

Practical Computed Tomography Scan Findings for Distinguishing Metopic Craniosynostosis from Metopic Ridging

Craig B. Birgfeld, MD*
 Carrie L. Heike, MD, MS†
 Faisal Al-Mufarrej, MD‡
 Adam Oppenheimer, MD§
 Shawn E. Kamps, MD¶
 Widya Adidharma, BS||
 Babette Siebold, PhD**

Background: Premature fusion of the metopic suture (ie, metopic craniosynostosis) can be difficult to discriminate from physiological closure of the metopic suture with ridging (MR). Yet, MCS is treated surgically, whereas MR is treated nonsurgically. Often, the diagnosis can be made by physical examination alone, but in difficult cases, a computed tomography (CT) scan can add additional diagnostic information.

Methods: We de-identified, randomized, and analyzed the CT scans of patients with MCS (n = 52), MR (n = 20) and age-matched normative controls (n = 52) to identify specific findings helpful in distinguishing between MCS and MR. Four expert clinicians were blinded to the clinical diagnosis and assessed each CT for features of the orbits, frontal bones, and inner table of calvaria.

Results: Although no single feature was diagnostic of MCS, we identified several signs that were correlated with MCS, MR, or controls. Features such as “posteriorly displaced frontal bone” and “frontal bone tangent to mid-orbit or medial” demonstrated higher correlation with MCS than MR and the addition of other features improves the accuracy of diagnosis as did inclusion of the interfrontal divergence angle.

Conclusion: The presence of a closed metopic suture in addition to other CT scan findings may improve the accuracy of diagnosing MCS, MR, and normocephaly. (*Plast Reconstr Surg Glob Open* 2019;7:e1944; doi: 10.1097/GOX.0000000000001944; Published online 14 March 2019.)

INTRODUCTION

Craniosynostosis is the premature fusion of one or more of the cranial sutures and occurs in approximately 1 in 2,000 births,¹ making it one of the most frequent

congenital conditions treated in craniofacial centers. The metopic suture typically closes between 2 and 24 months of age with average age of 6 months^{2,3} and is the only major calvarial suture that closes *physiologically* during infancy. Metopic craniosynostosis (MCS), premature fusion of the metopic suture, typically occurs in utero and causes restriction of growth of the frontal bones, which results in trigonocephaly. MCS represents 10–15%^{4,5} of all types of craniosynostosis, and recent reports suggest that the prevalence may be increasing.^{6–9} The cause of this upsurge is unknown, but concern has been raised that children with physiological closure of metopic suture associated with a metopic ridge (MR) are misdiagnosed as having MCS, and may undergo unnecessary cranial vault expansion surgery.¹⁰

Clinicians have used phenotypic findings¹⁰ and anthropometric measurements^{11–16} to differentiate between the surgical condition of MCS and the nonsurgical condition of MR. Computerized tomography is considered the gold standard for identification of premature fusion of most major cranial sutures; however, the metopic suture is closed in both MCS and MR, and radiographic evidence

From the *Department of Surgery, Division of Plastic Surgery, University of Washington, Seattle Children’s Hospital, Seattle, Wash.; †Department of Pediatrics, Division of Craniofacial Medicine, Seattle Children’s Hospital, Seattle, Wash.; ‡Department of Surgery, Division of Plastic Surgery, Wayne State University, Detroit, Mich.; §Oppenheimer Plastic Surgery, Orlando, Fla.; ¶Department of Radiology, Seattle Children’s Hospital, Seattle, Wash.; ||University of Washington, Seattle, Wash.; and **Seattle Children’s Hospital, Seattle Wash.

Received for publication March 9, 2018; accepted July 27, 2018.

Presented at the annual meeting of the Northwest Society of Plastic Surgeons, Poipu, HI, February 2016. Presented at ACPA annual meeting, Pittsburgh, PA, April 2018.

Copyright © 2019 The Authors. Published by Wolters Kluwer Health, Inc. on behalf of The American Society of Plastic Surgeons. This is an open-access article distributed under the terms of the Creative Commons Attribution-Non Commercial-No Derivatives License 4.0 (CCBY-NC-ND), where it is permissible to download and share the work provided it is properly cited. The work cannot be changed in any way or used commercially without permission from the journal.

DOI: 10.1097/GOX.0000000000001944

Disclosure: The authors have no financial interest to declare in relation to the content of this article.

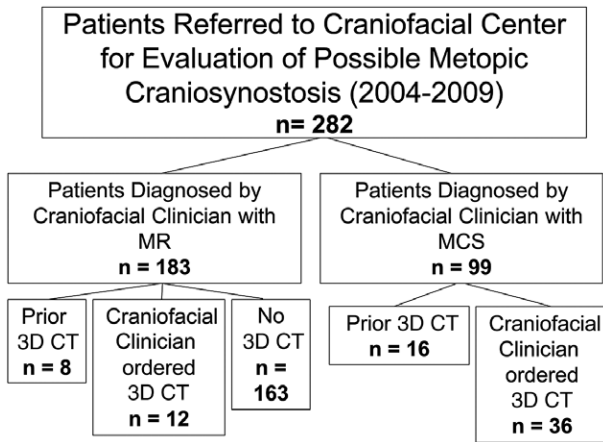


Fig. 1. Flowchart describing the inclusion criteria of our cohort of patients with MR and MCS who had available 3D CT scans.

of a closed metopic suture in a 5-month old is not necessarily indicative of MCS. We, therefore, sought to identify additional computed tomography (CT) scan findings that could differentiate between normocephaly, normocephaly with MR, and trigonocephaly due to MCS.

PATIENTS AND METHODS

Children who received a diagnosis of MR or MCS by a craniofacial provider at the Craniofacial Center at Seattle Children’s Hospital and had a CT scan available for review were included in this study. We identified children who were evaluated between the years of 2004 and 2009 for a clinical concern of either MR or MCS through the clinical craniofacial database and abstracted medical charts to determine each patient’s craniofacial diagnosis. Of the 282 patients evaluated, 183 (65%) received a clinical diagnosis of MR, while the remaining 99 (35%) were diagnosed with MCS. Of those diagnosed with MCS, 16 had a prior 3DCT scan obtained by the referring physician, while in the other, 36 had a CT scan ordered after diagnosis for surgical planning. Of those patients diagnosed with MR, 8 had a prior CT scan obtained by the referring physician, 12 had a CT scan ordered by the craniofacial physician to aid in diagnosis, and the remaining 163 were diagnosed without imaging (Fig. 1). Therefore, 72 participants met our eligibility criteria. The CT scans of patients with MR and MCS were de-identified and randomized with an age-matched, normative cohort of 52 CT scans of children *without* either craniosynostosis or metopic ridging for whom CT scan had been obtained for reasons that were not thought to affect their head shape (eg, patients with dermoid cysts). Axial, coronal, and 3D reconstruction images of these CT scans were made available to reviewers using Centricity (GE Health Imaging).

The CT scan findings of an omega sign³ and IFA^{11,17} have been associated with the diagnosis of MCS. We elicited additional signs via a web-based survey of 6 experienced craniofacial physicians regarding the CT scan findings, which are most informative for their diagnosis of MCS. Of these, the top 10 were included in this study (Table 1).

Table 1. CT Scan Findings Considered Clinically Relevant by Surveyed Clinicians for Diagnosing Metopic Craniosynostosis

Variables	Description
Upsloping rim	Superior orbital rim is oriented more vertically than horizontally
Ridge	Visible ridge over metopic suture
Pulled fontanelle	Anterior fontanelle is partially open down the metopic suture
Posteriorly displaced frontal bone	Posteriorly displaced lateral frontal bone
Orbital narrowing	The shape of the upper orbit is more narrow than usual
Omega sign	Indentation of the inner table of calvaria at the metopic suture is present
Medially displaced supraorbital nerves	The supraorbital neurovascular notch or foramina is displaced medially
Interorbital narrowing	Decreased distance between medial orbital walls
Frontal bone tangent	Frontal bone intersects the orbit at mid orbit or more medial when viewed from above
Diagnosis	Diagnosis of MCS, MR, or normocephaly
Closed metopic suture	Closed metopic suture

These findings were used to evaluate our cohort of CT scans by our expert raters.

Three craniofacial surgeons and 1 radiologist, blinded to the clinical diagnosis, reviewed the images. Raters were given a primer with images detailing the specific radiographic characteristics of interest, along with definitions (Figs. 2–7). They were asked to determine the presence or absence of these following findings: Upsloping superior orbital rim; closed metopic suture; ridge over metopic suture; orbital narrowing; interorbital narrowing; “pulled” anterior fontanelle; posteriorly displaced lateral frontal bone; frontal bone tangent to mid orbit or medial; medially displaced supraorbital nerve; presence or absence of omega sign; radiographic diagnosis of MCS, MR, or neither; and whether or not surgery would be recommended (Table 1). Raters’ findings were entered into a RedCap database. Interfrontal angle and interfrontal divergence angle (IFDA) as described by Wood et al.¹⁷ were calculated for each subgroup (MCS, MR, and controls) using Dolphin imaging software (Dolphin Imaging and Management Solutions 9200 Oakdale Ave. Suite 500 Chatsworth, Calif.; Fig. 8).

Data from the most senior surgeon (C.B.) was used to calculate the difference between groups defined by diagnosis using Pearsons chi-squared correlation. The intraclass correlation coefficient was used to estimate the level of agreement among the 4 raters. Linear regression models were fit to evaluate the association between each of the potentially diagnostic features and ultimate diagnosis of MCS, both individually and in pairwise combination with each of the other features. We report the R² statistics that measures the proportion of the variation in the dependent variable (clinical diagnosis of MCS or MR) as explained by the independent variable (specific features) in the linear regression model. Intraclass correlation coefficients and 95% confidence intervals were calculated to evaluate the between-rater agreement of presence or absence of specific features. All analyses were carried out using STATA

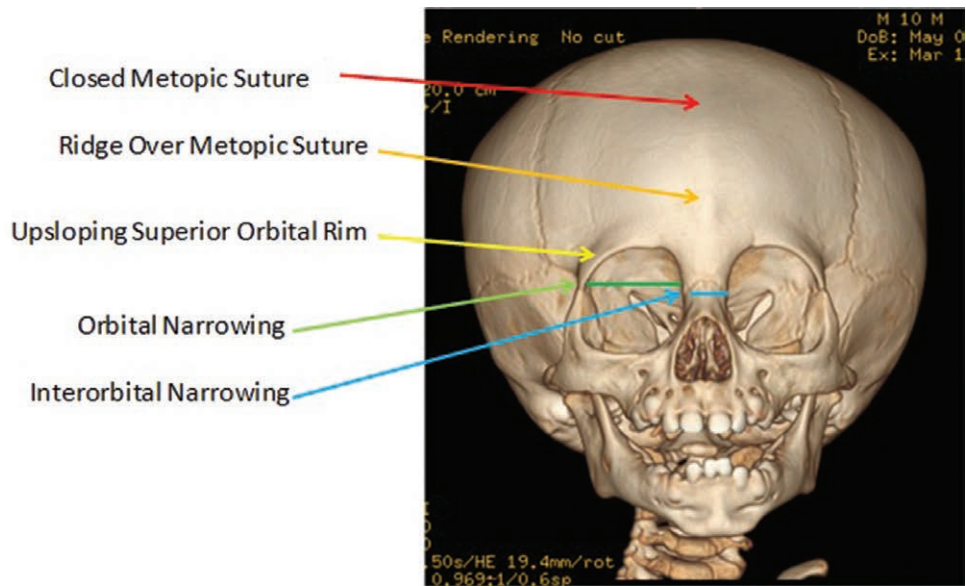


Fig. 2. CT scan findings of orbital features and metopic suture features in MCS as evaluated by our expert raters.

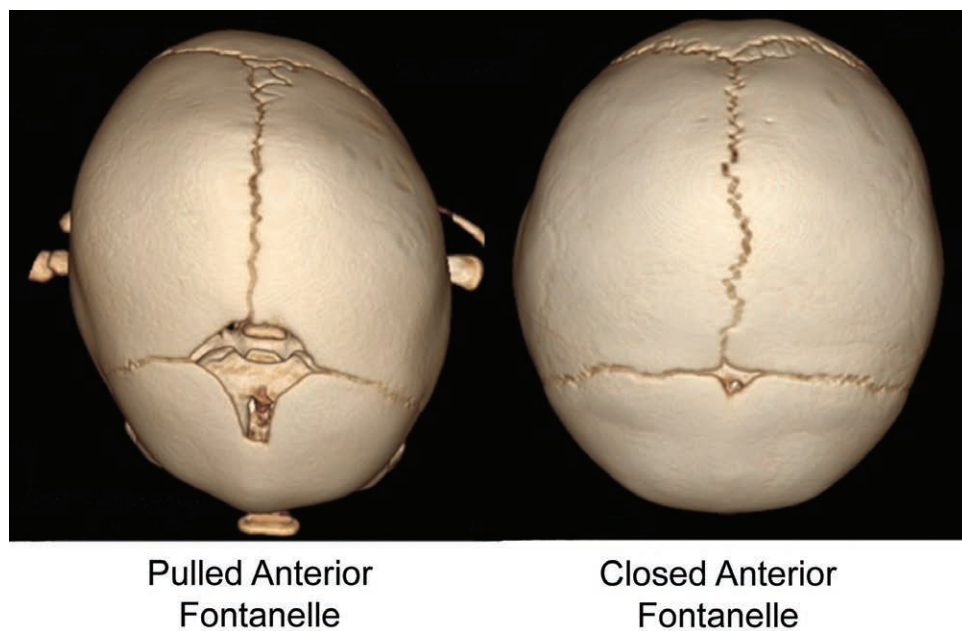


Fig. 3. Morphology of the anterior fontanelle.

(StataCorp. 2011. *Stata Statistical Software: Release 12*. College Station, Tex.: StataCorp LP).

RESULTS

The metopic suture was fused in all CTs of children with MR or MCS and 32 (62%) of the controls. Among the MCS cases, the presence of the other CT characteristics ranged from 15% (pulled anterior fontanelle) to 100% (ridge over metopic suture; Table 2). The prevalence of

the features among controls ranged from 0% (frontal bone tangent to midline) to 33% (pulled anterior fontanelle). No single characteristic was perfectly correlated with the clinical diagnosis.

The agreement between the ratings of patients' radiographic diagnosis was 0.89 (95% CI: 0.85–0.92). The intraclass correlation coefficients for the individual features ranged from 0.45 to 0.86 for the pulled anterior fontanelle and frontal bone tangent to midline, respectively. We identified moderate-to-strong inter-rater agreements for closed

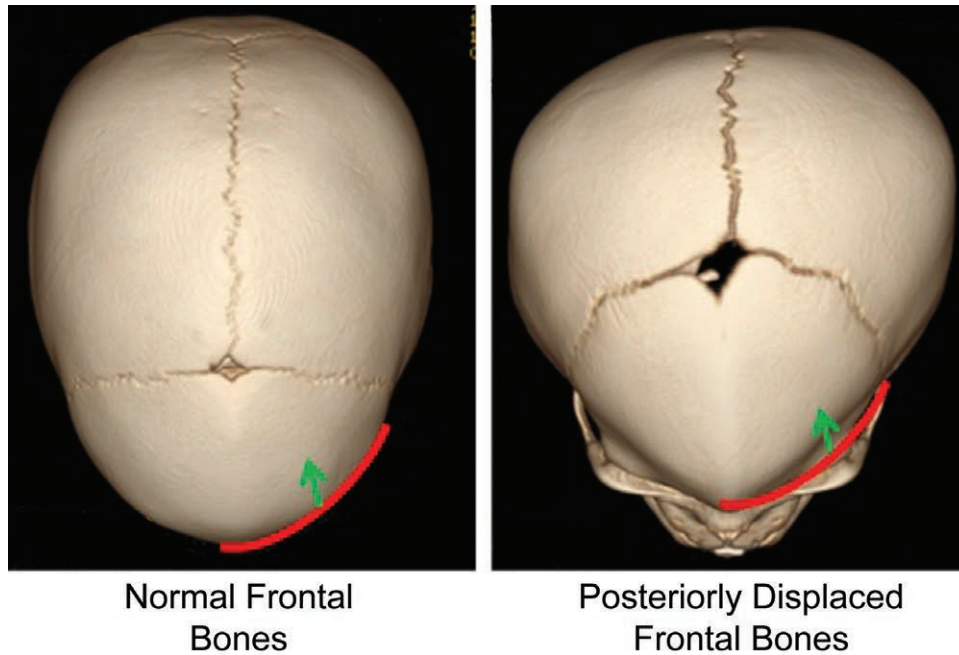


Fig. 4. Normal frontal bone morphology (A) compared with posteriorly repositioned frontal bones (B) found in trigonocephaly.

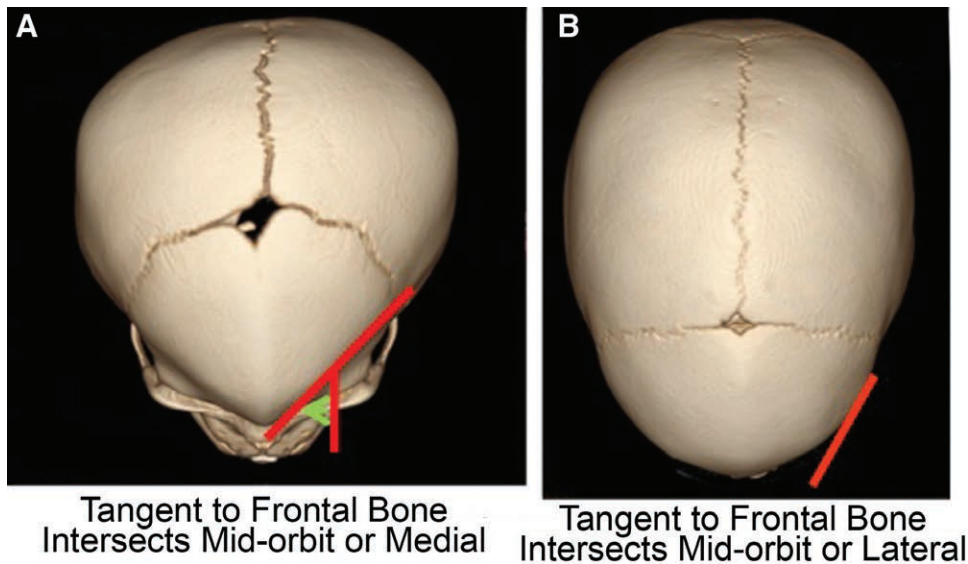


Fig. 5. When viewed from above, a tangent drawn to the frontal bone intersects the mid-orbit or more medial (A) or lateral to the mid orbit (B).

suture, metopic ridge, orbital narrowing, posteriorly displaced frontal bone, frontal bone tangent to mid-orbit, and omega sign, all with agreements greater than 0.6 (Table 3).

The characteristics that accounted for greater than 80% of the difference between the group diagnosed MCS versus controls were the presence of a metopic ridge and posterior displacement of the frontal bone with R squared values of 0.82 and 0.86, respectively (Table 4). Although the R squared values were higher with the addition of each of the

other variables in combination, no pairwise combination was 100% predictive of the ultimate diagnosis (Table 4).

The R squared values for the ability for each of the specific features to differentiate between MR and MCS are shown in Table 5. The presence of the metopic ridge accounted for 0.28 of the variation in the diagnosis, and 0.79 in the presence of the variable “posterior displacement of the frontal bone.” “Posterior displacement of the frontal bone” had the highest R squared value individually (0.69).

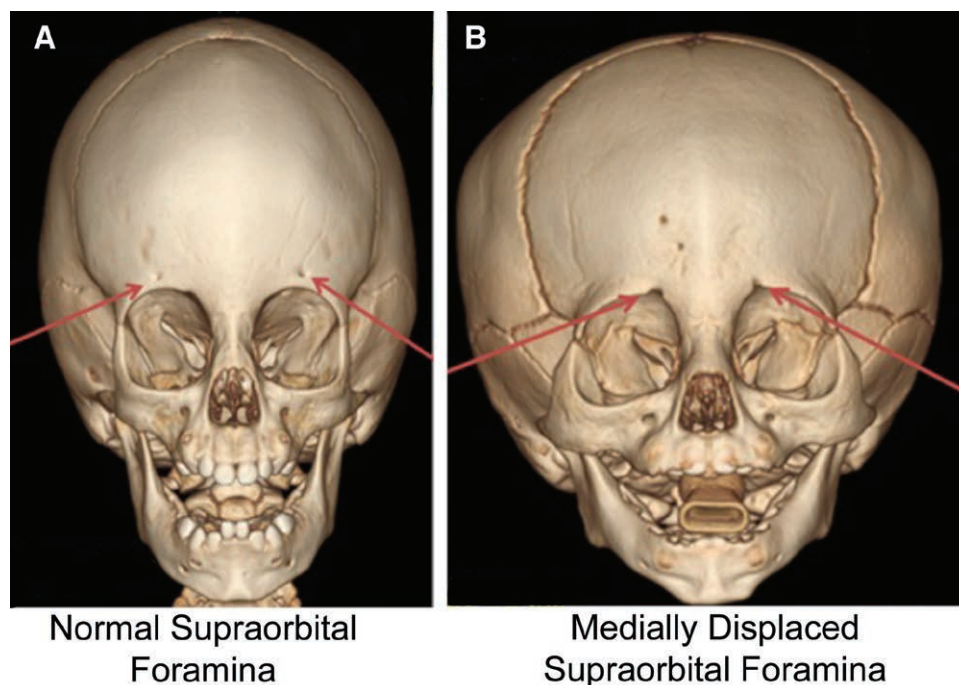


Fig. 6. Typical location of supraorbital foramina (A) compared with foramina that are located more medial (B).

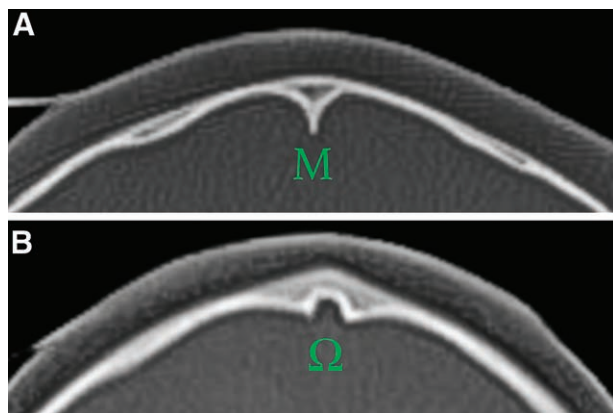


Fig. 7. This figure displays the “M” sign (A), “omega” sign (B).

This value was increased slightly when combined with upsloping rim, ridge, pulled fontanelle, orbital narrowing, omega sign, interorbital narrowing, or frontal bone tangent to midline (ranging from 0.70 to 0.75). The ability of the presence or absence of these features to discern between MR and MCS was lower than their ability to discern between metopic synostosis and controls.

The mean IFA for controls, MR, and MCS were 106.0, 101.6, and 98.4, respectively. The mean IFDA for controls, MR, and MCS were 151.9, 141.9, and 126.3, respectively. Comparisons among subgroups are shown in Table 6. In these comparisons, the interfrontal could only significantly discern between MCS and controls, whereas interfrontal divergence angle was statistically significant in distinguishing between MCS and MR, MCS and controls, and MR and controls.

DISCUSSION

Accurate diagnosis of craniosynostosis is paramount to appropriately identify infants for whom surgical expansion of the calvaria is recommended. Although cranial vault expansion has become safer,¹⁸ all surgical interventions carry risks—including the risk associated with exposure to anesthesia in young children.¹⁹ Additionally, if surgery is not performed either due to medical comorbidities, family preference, or mild phenotype, a child may still require closer follow-up, additional interventions,²⁰ and may have increased anxiety regarding their risk of elevated intracranial pressure inherent with craniosynostosis.^{20–27}

The diagnosis of craniosynostosis of the major calvarial sutures (metopic, coronal, sagittal, lambdoid) is often based solely upon physical evaluation of the head shape.²⁸ Although a CT scan demonstrating a fused suture can be obtained for diagnostic confirmation for many forms of synostosis, fusion of the metopic suture is an exception, given the frequency of physiologic closure in infants without a craniofacial condition. As expected, we observed a fused metopic suture in a high proportion of our control CT scans (62%). To complicate the diagnosis, as many as 25%²⁹ of children will develop a visible and palpable ridge over the physiologically closing metopic suture, which may resemble the ridge found among patients with true MCS despite a patent suture seen on CT scan.³⁰ Yet, a number of helpful CT scan findings exist, which can help to differentiate between patients with MCS and those with MR.

Frontal bone morphology appears to play the biggest role in the rater’s differentiation between MCS, MR, or normocephaly based on CT scan. This is not surprising since the narrowed forehead is frequently the reason for referral. When asked whether the frontal bones appeared

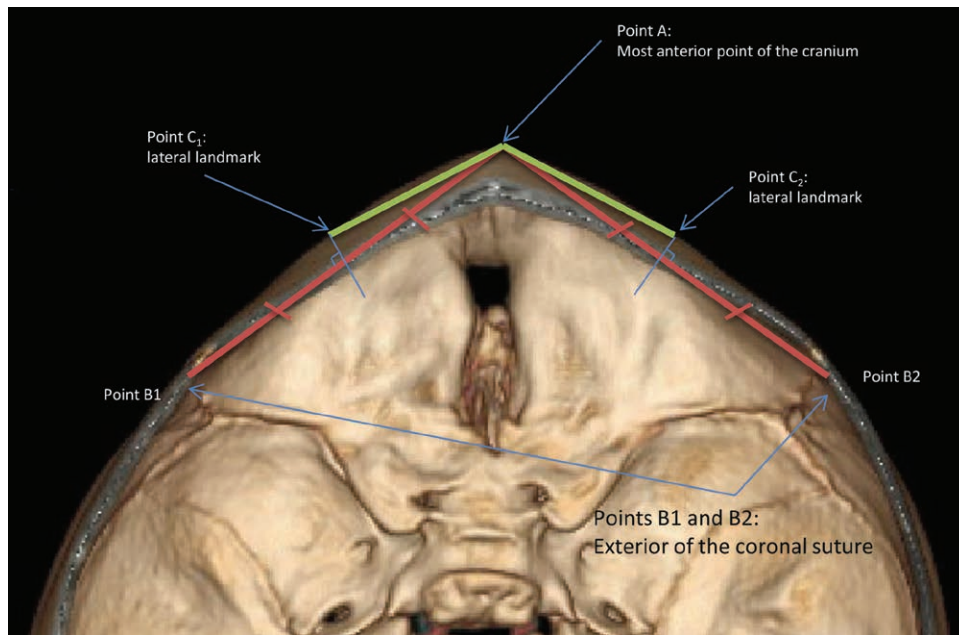


Fig. 8. The IFDA is the angle between the line segments connecting points A (most anterior point of the cranium) and C (the lateral landmark bilaterally); or $\angle C_1AC_2$. Steps to define this angle: (1) Using the CT cut normal to the midsagittal plane containing the opisthion and the tips of the clinoid processes, identify point A- the most anterior point of the cranium. (2) Points B1 and B2 are the points most exterior on the coronal sutures. (3) Points C1 and C2 are the most external crossing of the frontal bones where a ray perpendicular to the midpoint of the lines AB_1 and AB_2 .

to be posteriorly displaced, the raters found this to be true for only 2 (4.7%) controls and 3 (17.6%) patients with MR, while almost all (97.4%) patients with MCS had posteriorly displaced lateral frontal bones. Even more notable was the presence of straightened lateral frontal bones from which a tangent drawn would intersect the mid orbit or medial (0% control, 0% MR, and 78.9% of MCS). Other research has focused on the narrowness of the forehead as a diagnostic tool and even created a surrogate based on CT scan measurements.^{11,17,31} Indeed, in our analysis, the use of the IFDA was helpful in discerning between the subgroups of MCS, MR, and controls. But, the narrow forehead is not the only change associated with MCS. Alterations in orbital morphology have previously been described and seem to play an important role in diagnosing MCS in our study.

The raters found the upper orbits to be narrowed in only 1 control (2.1%) and 0 with MR while 27 (69.2%) of the patients with MCS displayed this finding. The distance between the orbits was also found to be decreased in only 1 control (2.1%) and 1 MR (5.6%), whereas 33 (68.8%) patients with MCS had decreased interorbital distances. However, having an upsloping superior orbital rim was less predictive since it was found to be present in 23.3% of controls, 33.3% of patients with MR, and 71.8% of patients with MCS.

We identified a few CT scan findings that were less indicative of MCS than anticipated a priori. A “pulled” anterior fontanelle was a common finding among controls (66.7%), children with MR (75.0%), and patients with MCS (85.0%). Medially displaced supraorbital

nerves were much more common in MCS (90.9%), but were also identified in patients with MR (37.5%) and controls (15.8%). The presence of an omega sign was much more common in MCS (69.2%) and was observed in as many as 10% of MR and 3.9% of control CTs. Moreover, this sign was notably absent in 30.8% of patients with MCS.

No single CT scan finding was singularly diagnostic of MCS. In fact, combining CT scan traits, while improving accuracy, still does not bring the predictive value to 100%. It could be that there is no set of characteristics that are universally associated with MCS. Perhaps the metopic suture fuses at different time points of development, thereby variably affecting frontal bones and orbits. Possibly, a lack of agreement among our raters or a disagreement between our raters and the diagnosing clinicians is responsible for this lack of complete consensus. It could also be that a few patients in the cohort were originally diagnosed with MCS by their providing clinician based on physical examination findings, which were not included in our radiographic study.

The agreement between raters ranged from 0.89 to 0.65, with 6 of the evaluated features below the 0.7 threshold considered to be good. This finding speaks to the larger problem of developing an agreement algorithm between surgeons for the diagnosis of MCS. Even if we were able to define a set of criteria to allow for definitive diagnosis of MCS, we must be able to rely on diagnosticians being able to agree on what constitutes any one of these features. Particularly among those features deemed to have utility in predicting the presence or absence of

Table 2. Prevalence of Specific Ratings among Controls, Metopic Ridge Cases, and Metopic Synostosis Cases (Defined by Clinical Diagnosis Abstracted from Medical Records)

	Control n (%)	Metopic Ridge n (%)	Metopic Craniosynostosis n (%)	Between-group Distribution	
				Three Group <i>P</i>	MR Versus MC <i>P</i>
Total	52 (100.0)	20 (100.0)	52 (100.0)		
Diagnosis					
Metopic craniosynostosis	1 (2.0)	0 (0.0)	43 (82.7)	<0.001	<0.001
Metopic ridge	4 (7.8)	13 (65.0)	9 (17.3)		
Neither	46 (90.2)	7 (35.0)	0 (0.0)		
Missing	1	0	0		
Clinical history of surgery					
No	52 (100.0)	20 (38.5)	4 (7.7)	<0.001	<0.001
Yes	0 (0.0)	0 (0.0)	48 (92.3)		
Missing	0	0	0		
Would rater recommend surgery					
No	51 (100.0)	20 (100.0)	9 (18.4)	<0.001	<0.001
Yes	0 (0.0)	0 (0.0)	40 (81.6)		
Missing	1	0	3		
Upsloping superior orbital rim					
No	33 (76.7)	10 (66.7)	11 (28.2)	<0.001	0.009
Yes	10 (23.3)	5 (33.3)	28 (71.8)		
Missing	9	5	13		
Closed metopic suture					
No	19 (37.3)	0 (0.0)	0 (0.0)	<0.001	<0.001
Yes	32 (62.7)	20 (100.0)	52 (100.0)		
Missing	1	0	0		
Ridge over metopic suture					
No	46 (90.2)	7 (35.0)	0 (0.0)	<0.001	<0.001
Yes	5 (9.8)	13 (65.0)	52 (100.0)		
Missing	1	0	0		
Orbital narrowing present					
No	41 (97.6)	16 (100.0)	12 (30.8)	<0.001	<0.001
Yes	1 (2.4)	0 (0.0)	27 (69.2)		
Missing	10	4	13		
Intraorbital narrowing present					
No	47 (97.9)	17 (94.4)	15 (31.3)	<0.001	<0.001
Yes	1 (2.1)	1 (5.6)	33 (68.8)		
Missing	4	2	4		
Pulled anterior fontanelle					
No	28 (66.7)	12 (75.0)	34 (85.0)	0.16	0.38
Yes	14 (33.3)	4 (25.0)	6 (15.0)		
Missing	10	4	12		
Posteriorly displaced lateral frontal bone					
No	41 (95.3)	14 (82.4)	1 (2.6)	<0.001	<0.001
Yes	2 (4.7)	3 (17.6)	38 (97.4)		
Missing	9	3	13		
Frontal bone tangent to midline					
No	43 (100.0)	17 (100.0)	8 (21.1)	<0.001	<0.001
Yes	0 (0.0)	0 (0.0)	30 (78.9)		
Missing	9	3	14		
Medially displaced supraorbital nerves					
No	32 (84.2)	10 (62.5)	3 (9.1)	<0.001	<0.001
Yes	6 (15.8)	6 (37.5)	30 (90.9)		
Missing	14	4	19		
Omega sign present					
No	49 (96.1)	18 (90.0)	16 (30.8)	<0.001	<0.001
Yes	2 (3.9)	2 (10.0)	36 (69.2)		
Missing	1	0	0		

MCS (such as posteriorly displaced frontal bone, frontal bone tangent to midline; pulled fontanelle, ridge, upsloping rim), attention should be given in the course of surgeons training to standardize the identification of these features. The agreement reported in the current study is likely an overestimate of the true level of agreement between surgeons since (1) they come from a single center and several have been trained by the senior author participating in this study and (2) they were trained to refer to and consult the images and primer that was developed

for the purposes of standardizing rater's understanding of what feature, specifically, was being evaluated.

A potential limitation of this study stems from our reliance on clinically indicated CT images. As we relied on retrospective data collection from clinician's notes—there was no clear standardization in terms of what constituted diagnostic criteria, beyond that which is assumed in one craniofacial center between a group of plastic surgeons who specialize in caring for children with these types of conditions. The subgroup of patients with clinically in-

Table 3. Intraclass Correlation Coefficient for Each Variable

Diagnosis	0.89	0.85–0.92
Frontal bone tangent to mid-orbit	0.86	0.81–0.90
Recommend surgery?	0.85	0.80–0.89
Closed suture	0.85	0.80–0.89
Ridge	0.79	0.73–0.85
Omega sign	0.75	0.68–0.81
Orbital narrowing	0.67	0.56–0.75
Posteriorly displaced frontal bone	0.64	0.53–0.73
Interorbital narrowing	0.56	0.46–0.67
Medially displaced supraorbital nerve	0.52	0.38–0.64
Upsloping superior orbital rim	0.51	0.39–0.63
Pulled anterior fontanelle	0.45	0.32–0.58

*A measure of the reliability between each rater

dedicated CTs likely resulted in selection bias, as only the children with more severe alterations in head shape would have undergone radiographic imaging. The impact of this bias on our findings likely resulted in an attenuation of the ability of each feature evaluated in its ability to differentiate between MR and MCS, to a degree. So the power of discernment of each of these features is likely higher than what we have reported here. However, we are not advocating for more frequent imaging; imaging as a tool to aid in diagnosis should be used only as a last resort when a clinical diagnosis is particularly challenging. As such, this subgroup of patients likely does reflect the images that providers are considering when evaluating whether a child’s head meets or exceeds the threshold for a diagnosis of MCS and whether surgery is warranted.

Although many surgeons feel confident in diagnosing metopic craniosynostosis and recommending surgical intervention based on physical examination alone, there remains a gray area of overlap between “mild” metopic craniosynostosis and a narrow forehead with physiological metopic ridging. Some surgeons may dismiss these patients since they do not require surgery, while others may operate. Without guidance, surgeons may choose to perform unnecessary surgical interventions. Moreover, even if the child receives a diagnosis of craniosynostosis but the patient’s skull changes are considered too “mild” to need surgery, then they require additional follow-up and the family may incur undue stress and worry about their child who has been diagnosed with a congenital condition. Therefore, it is paramount to make an accurate diagnosis with all the information available.

In cases of severe trigonocephaly or clear normocephaly with metopic ridging, a CT scan may be unnecessary to confirm the diagnosis. However, when the diagnosis is in question, a CT scan can be beneficial in improving accuracy if findings above and beyond a fused metopic suture are analyzed. The decision to operate is still one that each surgeon must make on his/her own based on the risks of surgery and the perceived ability to improve the patient’s condition surgically. Although there is no single CT scan finding that can make this decision for the surgeon, there are radiographic details that are more likely associated with MCS than MR and normocephaly.

Table 4. The Ability of Specific Features to Differentiate between Cases of Metopic Synostosis (MCS) and Controls Alone and in Combination with a Second Variable using R² Statistics

	Ridge	Pulled fontanelle	Post displ. Frontal bone	Orbital narrowing	Omega sign	Medialized s.o. nerves	Interorbital narrowing	Frontal bone tangent	Diagnosis	Closed met. Suture
Upsloping rim	0.91	0.26	0.86	0.52	0.56	0.61	0.47	0.66	0.87	0.37
Ridge	0.82	0.91	0.92	0.91	0.83	0.95	0.89	0.92	0.85	0.82
Pulled fontanelle	0.91	0.05	0.91	0.54	0.52	0.56	0.44	0.67	0.87	0.27
Post displ. Frontal bone	0.92	0.91	0.86	0.86	0.86	0.89	0.95	0.87	0.89	0.86
Orbital narrowing	0.91	0.54	0.86	0.49	0.57	0.71	0.57	0.67	0.87	0.56
Omega sign	0.83	0.52	0.86	0.57	0.46	0.71	0.63	0.68	0.85	0.52
Medial displaced s.o. nerves	0.95	0.56	0.89	0.71	0.71	0.56	0.66	0.77	0.94	0.59
Interorbital narrowing	0.89	0.44	0.95	0.57	0.63	0.66	0.49	0.67	0.91	0.57
Frontal bone tangent	0.92	0.67	0.87	0.67	0.68	0.77	0.67	0.67	0.87	0.7
Diagnosis	0.85	0.87	0.89	0.87	0.85	0.94	0.91	0.87	0.84	0.84
Closed met. Suture	0.82	0.27	0.86	0.56	0.52	0.59	0.57	0.7	0.84	0.23
No second variable	0.82	0.05	0.86	0.49	0.46	0.56	0.49	0.67	0.84	0.23

Cells are color coded in gradations ranging from yellow (highest) to green (lowest).

Table 5. The Ability of Specific Features to Differentiate between Cases of Metopic Synostosis (MCS) and Metopic Ridges (MR) Alone and in Combination with a Second Variable via R² Statistics

	Ridge	Pulled fontanelle	Post displ. Frontal bone	Orbital narrowing	Omega sign	Medialized s.o. nerves	Interorbital narrowing	Frontal bone tangent	Diagnosis	Closed met. Suture
Upsloping rim	0.31	0.13	0.74	0.39	0.37	0.4	0.29	0.51	0.64	0.12
Ridge	0.28	0.22	0.72	0.49	0.42	0.4	0.47	0.59	0.63	0.28
Pulled fontanelle	0.22	0.01	0.75	0.42	0.34	0.36	0.27	0.53	0.64	0.01
Post displ. Frontal bone	0.72	0.75	0.69	0.71	0.72	0.66	0.7	0.74	0.78	0.69
Orbital narrowing	0.49	0.42	0.71	0.4	0.45	0.56	0.43	0.53	0.66	0.4
Omega sign	0.42	0.34	0.72	0.45	0.28	0.51	0.43	0.55	0.63	0.28
Medially displaced s.o. nerves	0.4	0.36	0.66	0.56	0.51	0.32	0.44	0.65	0.72	0.32
Interorbital narrowing	0.47	0.27	0.7	0.43	0.43	0.44	0.32	0.54	0.69	0.32
Frontal bone tangent	0.59	0.53	0.74	0.53	0.55	0.65	0.54	0.54	0.65	0.54
Diagnosis	0.63	0.64	0.78	0.66	0.63	0.72	0.69	0.65	0.63	0.63
Closed met. Suture	0.28	0.01	0.69	0.4	0.28	0.32	0.32	0.54	0.63	0
No second variable	0.28	0.01	0.69	0.4	0.28	0.32	0.32	0.54	0.63	0

Cells are color coded in gradations ranging from yellow (highest) to green (lowest).

Table 6. Means and Mean Differences in Measurements of the Interfrontal Angle and Interfrontal Divergence Angle between CT Images of Patients with Metopic Craniosynostosis (MCS) Versus Metopic Ridges (MR) Versus Controls

Angle	Controls		MR		MCS		MCS Versus MR		MCS Versus Control		MR Versus Control	
	N	μ (sd)	N	μ (sd)	N	μ (sd)	Mean Difference (95% CI)	P	Mean Difference (95% CI)	P	Mean Difference (95% CI)	P
Interfrontal	41	106 (9)	22	102 (10.4)	61	98.4 (10.6)	-3.2 (-8.4,2)	0.22	-7.6 (-11.6,-3.6)	<0.01	-4.4 (-9.4,0.7)	0.087
Interfrontal divergence	41	151.9 (6)	22	141.9 (11)	61	126.3 (10)	-15.7 (-20.9,-10.5)	<0.01	-25.6 (-29.2,-22.1)	<0.01	-9.9 (-14.3,-5.6)	<0.01

Additionally, even if surgery is not recommended, making the diagnosis of craniosynostosis still must be considered seriously as it carries with it the possibility of increased burden of care and familial stress. In difficult cases, we endorse the use of all available information to make an accurate diagnosis.

Craig Birgfeld, MD

M/S OB 9.520

PO Box 5371

Seattle Children’s Hospital

4800 Sand Point Way

Seattle, WA 98105

E-mail: craig.birgfeld@seattlechildrens.org

REFERENCES

1. Kolar JC. An epidemiological study of nonsyndromal craniosynostoses. *J Craniofac Surg.* 22:47–49.
2. Vu HL, Panchal J, Parker EE, et al. The timing of physiologic closure of the metopic suture: a review of 159 patients using reconstructed 3D CT scans of the craniofacial region. *J Craniofac Surg.* 2001;12:527–532.
3. Weinzwieg J, et al. Metopic synostosis: defining the temporal sequence of normal suture fusion and differentiating it from synostosis on the basis of computed tomography images. *Plast Reconstr Surg.* 2003;112:1211–1218.
4. Shillito J, Jr., Matson DD. Craniosynostosis: a review of 519 surgical patients. *Pediatrics.* 1968;41:829–853.
5. Anderson FM, Geiger L. Craniosynostosis: a survey of 204 cases. *J Neurosurg.* 1965;22:229–240. doi:10.3171/jns.1965.22.3.0229.
6. Selber J, et al. The changing epidemiologic spectrum of single-suture synostoses. *Plast Reconstr Surg.* 2008;122:527–533.
7. Di Rocco F, Arnaud E, Renier, D. Evolution in the frequency of nonsyndromic craniosynostosis. *J Neurosurg Pediatr.* 2009;4: 21–25.
8. Di Rocco F, Arnaud E, Meyer P, et al. Focus session on the changing “epidemiology” of craniosynostosis (comparing two quinquennia: 1985–1989 and 2003–2007) and its impact on the daily clinical practice: a review from Necker Enfants Malades. *Childs Nerv Syst.* 2009;25:807–811.
9. van der Meulen J, et al. The increase of metopic synostosis: a pan-European observation. *J Craniofac Surg.* 2009;20:283–286.
10. Birgfeld CB, et al. Making the diagnosis: metopic ridge versus metopic craniosynostosis. *J Craniofac Surg.* 2013;24:178–185.
11. Kellogg R, Allori AC, Rogers GF, et al. Interfrontal angle for characterization of trigonocephaly: part 1: development and validation of a tool for diagnosis of metopic synostosis. *J Craniofac Surg.* 2012;23:799–804.
12. Kolar JC, Salter EM. Preoperative anthropometric dysmorphism in metopic synostosis. *Am J Phys Anthropol.* 1997;103: 341–351.
13. Havlik RJ, Azurin DJ, Bartlett SP, et al. Analysis and treatment of severe trigonocephaly. *Plast Reconstr Surg.* 1999;103:381–390.
14. Ruiz-Correa S, et al. New severity indices for quantifying single-suture metopic craniosynostosis. *Neurosurgery.* 2008;63:318–324; discussion 324-315.
15. Fearon JA, Ruotolo RA, Kolar JC. Single sutural craniosynostoses: surgical outcomes and long-term growth. *Plast Reconstr Surg.* 2009;123:635–642.
16. Friede H, Alberius P, Lilja J, et al. Trigonocephaly: clinical and cephalometric assessment of craniofacial morphology in operated and nontreated patients. *Cleft Palate J.* 1990;27:362–367; discussion 368.
17. Wood BC, et al. What’s in a Name? Accurately diagnosing metopic craniosynostosis using a computational approach. *Plast Reconstr Surg.* 2016;137:205–213.

18. Birgfeld CB, et al. Safety of open cranial vault surgery for single-suture craniosynostosis: a case for the multidisciplinary team. *J Craniofac Surg*. 2015;26:2052–2058.
19. Barritt J, Brooksbank M, Simpson D. Scaphocephaly: aesthetic and psychosocial considerations. *Dev Med Child Neurol*. 1981;23:183–191.
20. Wall SA, Thomas GP, Johnson D, et al. The preoperative incidence of raised intracranial pressure in nonsyndromic sagittal craniosynostosis is underestimated in the literature. *J Neurosurg Pediatr*. 2014;14:674–681.
21. Arnaud E, Renier D, Marchac D. Prognosis for mental function in scaphocephaly. *J Neurosurg*. 1995;83:476–479.
22. Eley KA, Johnson D, Wilkie AO, et al. Raised intracranial pressure is frequent in untreated nonsyndromic unicoronal synostosis and does not correlate with severity of phenotypic features. *Plast Reconstr Surg*. 2012;130:690e–697e.
23. Gault DT, Renier D, Marchac D, et al. Intracranial pressure and intracranial volume in children with craniosynostosis. *Plast Reconstr Surg*. 1992;90:377–381.
24. Renier D, Lajeunie E, Arnaud E, et al. Management of craniosynostoses. *Childs Nerv Syst*. 2000;16:645–658.
25. Renier D, Sainte-Rose C, Marchac D, et al. Intracranial pressure in craniostenosis. *J Neurosurg*. 1982;57:370–377.
26. Thompson DN, Harkness W, Jones B, et al. Subdural intracranial pressure monitoring in craniosynostosis: its role in surgical management. *Childs Nerv Syst*. 1995;11:269–275.
27. Thompson DN, Malcolm GP, Jones BM, et al. Intracranial pressure in single-suture craniosynostosis. *Pediatr Neurosurg*. 1995;22:235–240.
28. Fearon JA, Singh DJ, Beals SP, et al. The diagnosis and treatment of single-sutural synostoses: are computed tomographic scans necessary? *Plast Reconstr Surg*. 2007;120:1327–1331.
29. Cohen MJ, MacLean RE, eds. *Craniosynostosis: Diagnosis, Evaluation and Management*. 2nd ed. Oxford University Press; 2000.
30. Hashim PW, Patel A, Chang CC, et al. Does an elevated bony ridge along the course of the metopic suture equal metopic synostosis? Implications for management. *J Craniofac Surg*. 2014;25:55–58.
31. Nguyen DC, et al. Are endoscopic and open treatments of metopic synostosis equivalent in treating trigonocephaly and hypotelorism? *J Craniofac Surg*. 2015;26:129–134.